Equine Laminitis

Gary M. Baxter

Colorado State University

The Equine Hospital
Colorado State University

Definitions

- Inflammation of the laminae
  - Numerous inciting causes
  - Laminitis vs. “founder”
- Separation of the dermal and epidermal junction
  - Attachment of coffin bone to hoof wall
- Displacement of the coffin bone
  - Rotation
  - Sinking
  - Combination of the two

Coffin Bone Displacement

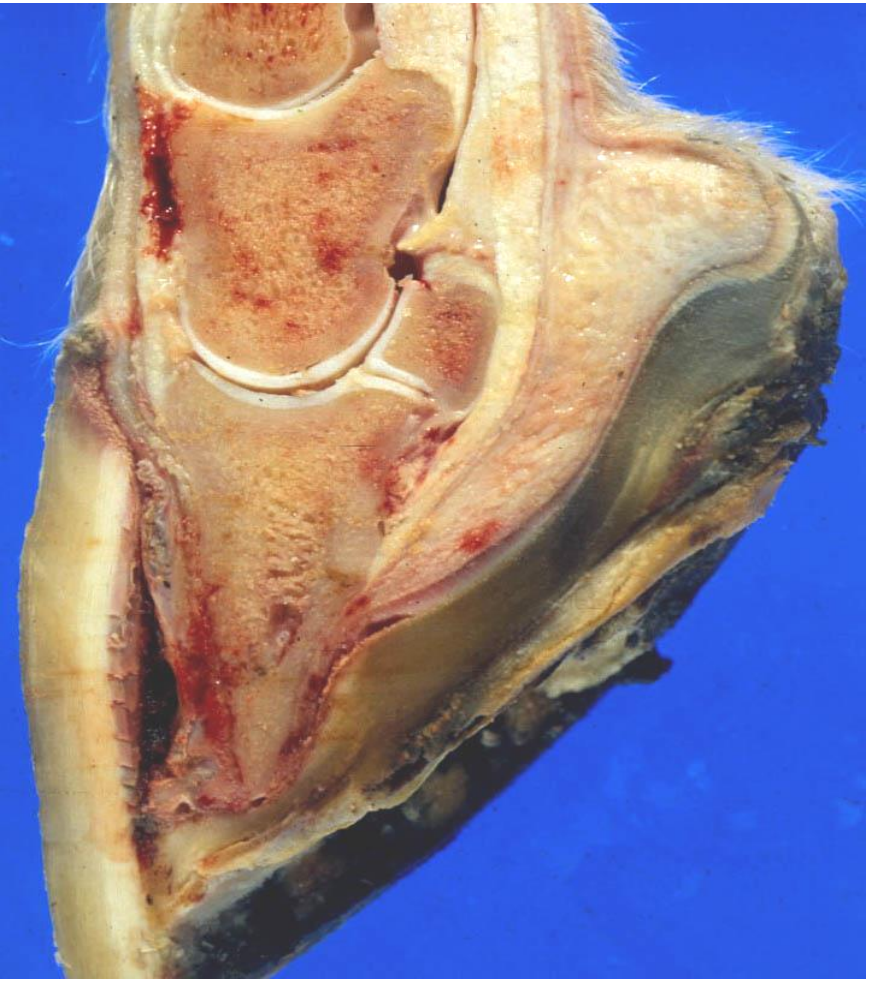

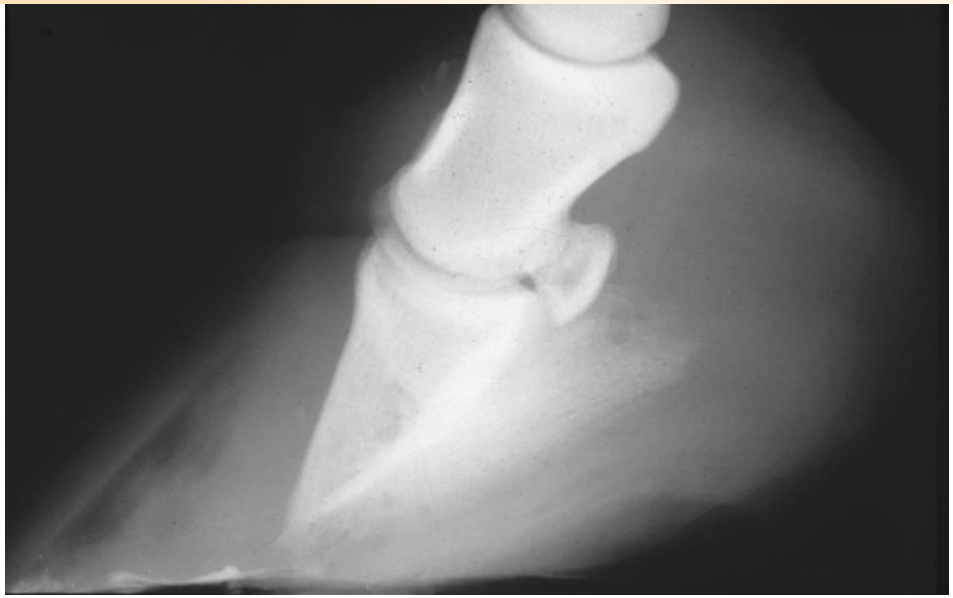

Clinical Forms

- **Gastrointestinal/toxic**
  - Grain overload, grass founder
  - Metritis, retained placenta, colitis, colic
- **Musculoskeletal/mechanical**
- **Metabolic/local**
  - Cushing's disease
  - Metabolic syndrome
  - Corticosteroids
- **Idiopathic**

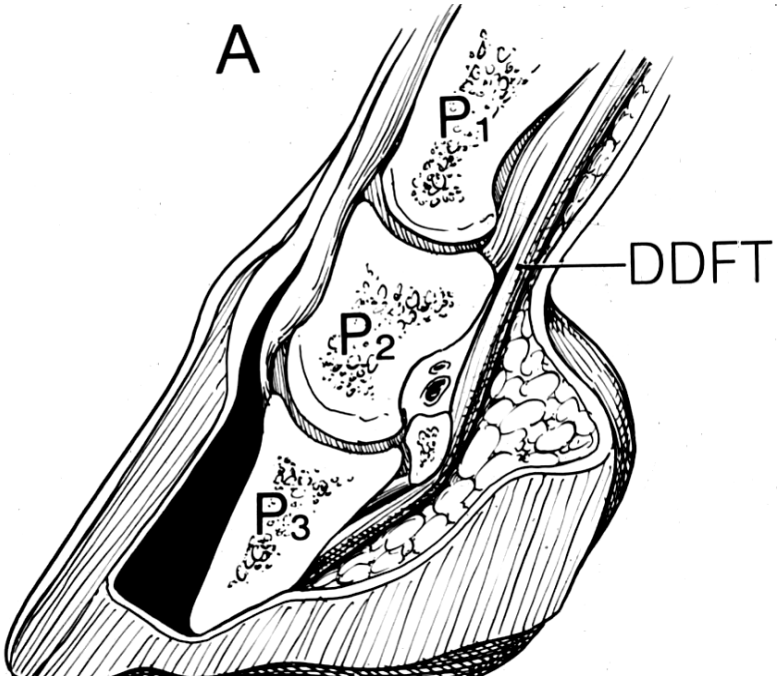

Predisposing Factors

- Systemic illness (toxemia)
- Excessive carbohydrate/grass
- Metabolic/weight problems
  - Increased glucose/insulin resistance
- Older horses and mares
  - Non-Thoroughbred breeds
- Unilateral lameness
- Long toe/low heel
  - Hard surfaces

Stages of Laminitis

- Developmental – before clinical signs
- Acute
  - Clinical signs only
  - No movement of coffin bone on radiographs
- Chronic
  - Movement of coffin bone within hoof
- Subacute?
  - In between the acute and chronic stages

Clinical Signs

- Lameness especially when turned
  - Worse on hard surfaces
  - Shifting weight between limbs
- Increased digital pulses
- Heat over dorsal hoof wall
- Both front feet commonly affected
  - All four feet (very sick horses)
  - Both rear feet (draft horses?)
  - Single foot (excessive weight-bearing)

Laminitis

Disease Process

- Variable developmental period
  - Grain overload – 24-72 hours
- Much happening in foot before laminar damage and clinical signs
- Minimal control over initial laminar damage
- Many horses with mild acute/subacute laminitis may not be recognized

Gross Pathology

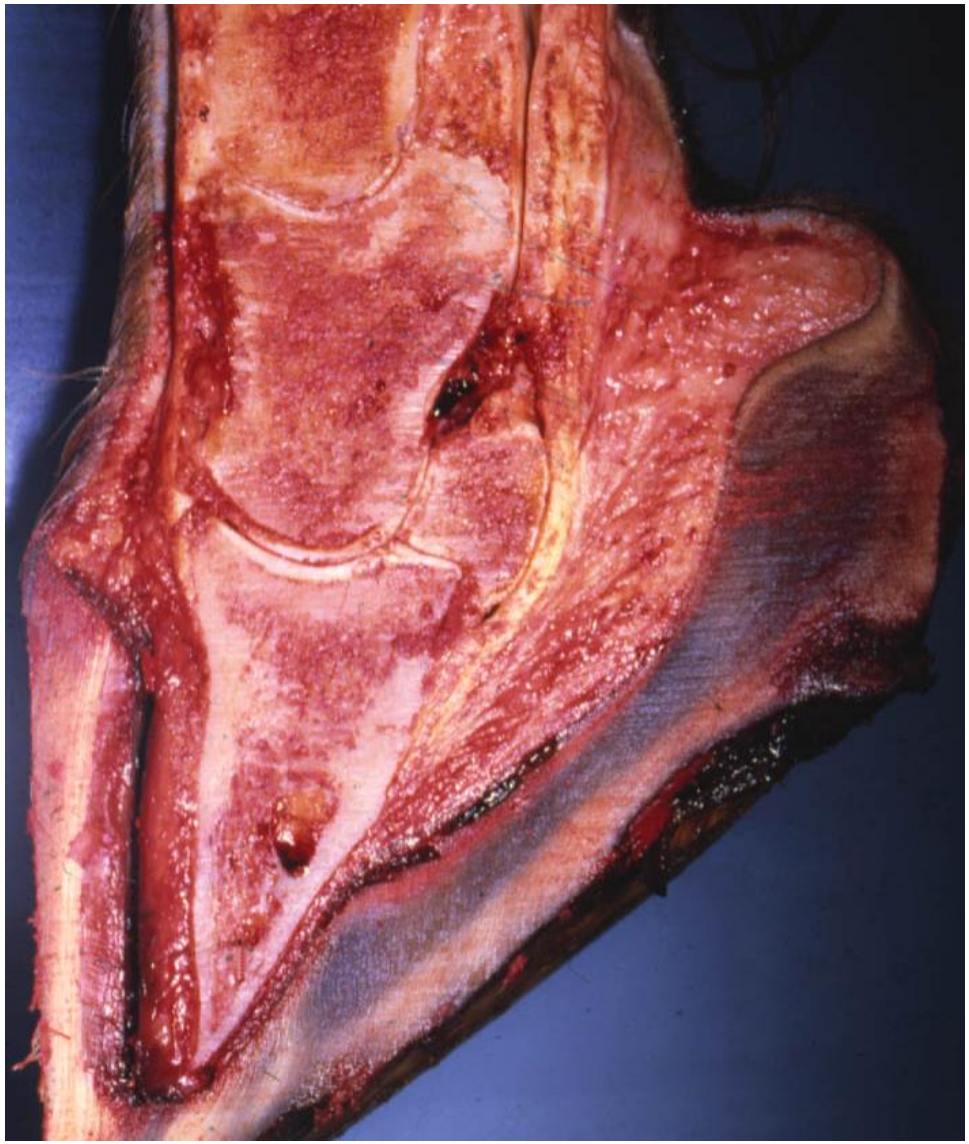

1. Edema - compartment syndrome

2. Hemorrhage

3. Laminar separation

4. Structural damage

Physiologic Alterations

- Hypertension
- Sympathetic stimulation/tachycardia
- Systemic/local coagulopathy
- Metabolic alterations

Causes of Laminitis?

- Several potential theories
  - Vascular theory
  - Toxic/enzymatic theory
  - Traumatic/mechanical theory
  - Glucose/insulin resistance theory
- Common end-result in the foot?
  - Inflammation
  - Breakdown of basement membrane of laminae
  - Separation of sensitive and insensitive laminae

Vascular Theory

- Too little blood to foot
- Laminar ischemia
- Reflex hyperemia – compartment syndrome/reperfusion
- Secondary inflammation
- Structural failure of laminae

Toxic/Enzymatic Theory

- Excessive blood to foot
- "Trigger factors" within the blood (from gut or uterus) initiate damage
- Several enzymes/mediators damage basement membrane
- Secondary inflammation
- Structural failure of laminae

Mechanical Theory

- Different from “classic” GI form
- Traumatic tearing of laminae from excessive weight bearing?
- Pain contributes to increased cortisol
  - Increased insulin?
  - Vasospasm of digital vessels?
- Secondary inflammation
- Structural failure of laminae

Glucose/IR Theory

- Hyperglycemia/insulin resistance
  - Impaired blood flow
  - Direct effect of increased insulin
- Impaired glucose uptake
  - Laminar cells have high glucose requirement
- Secondary inflammation
- Structural failure of laminae

Diagnosis

- Clinical signs
  - Increased digital pulses
  - Heat over dorsal hoof wall
  - Variable lameness but often severe
  - Heel-toe landing/hoof distortion in chronic cases
  - Pain over toe with hoof testers
- Local anesthesia
  - Improve with palmar digital, basi-sesamoid or abaxial blocks
- Radiography
  - Rotation, sinking or both

Chronic Laminitis

Radiology – “Rotation”

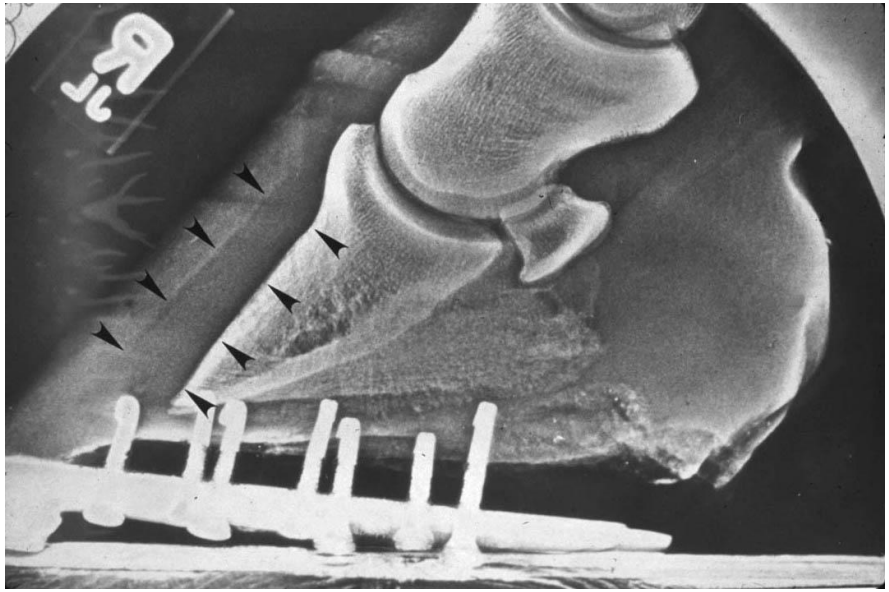

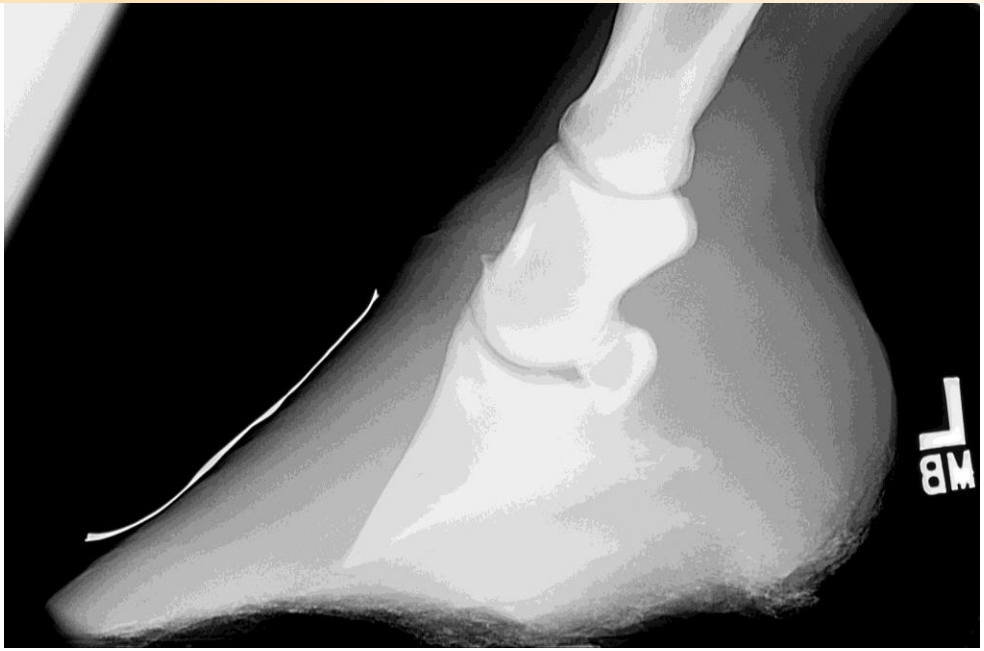

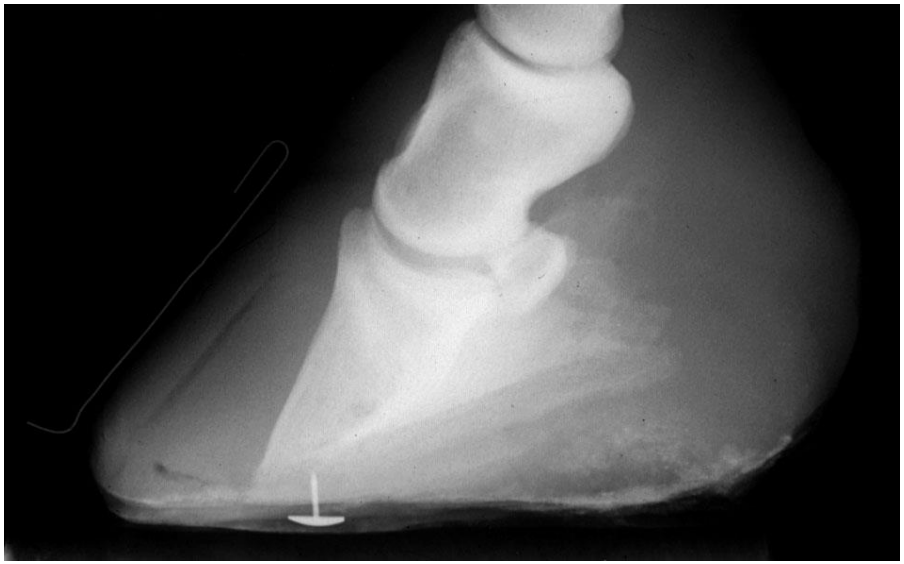

Radiology – “Sinking”

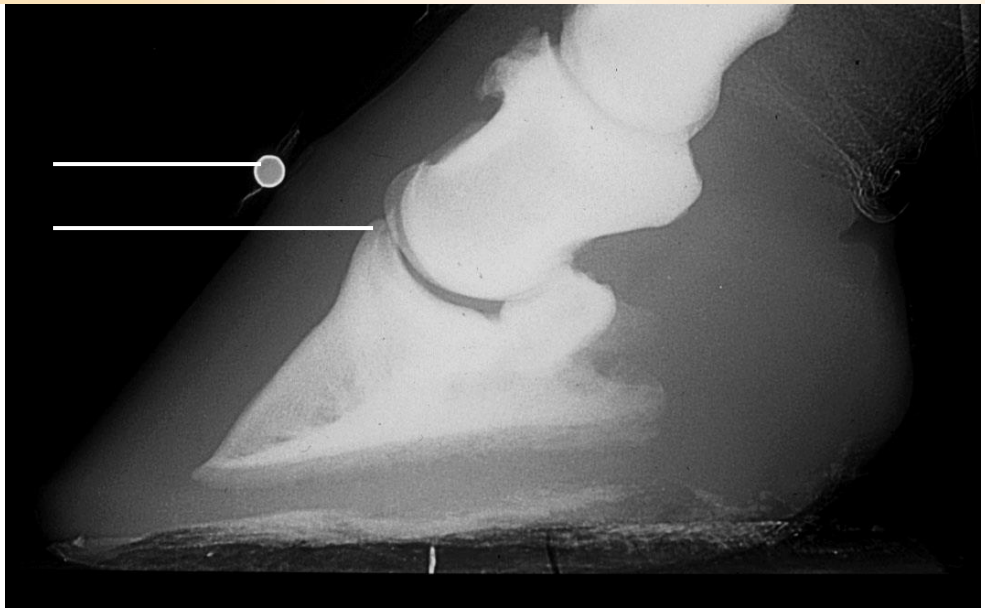

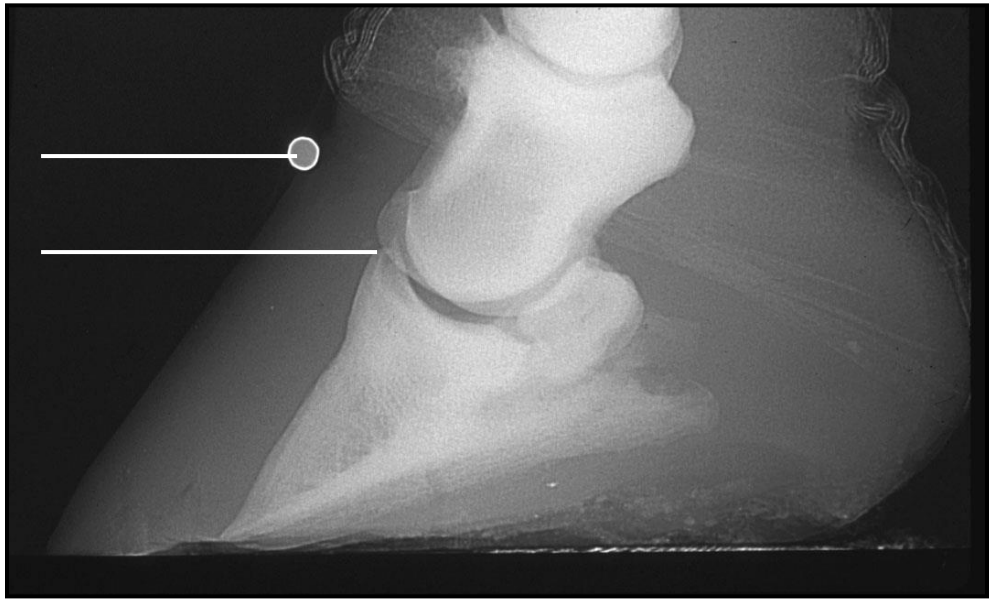

Radiology - chronic

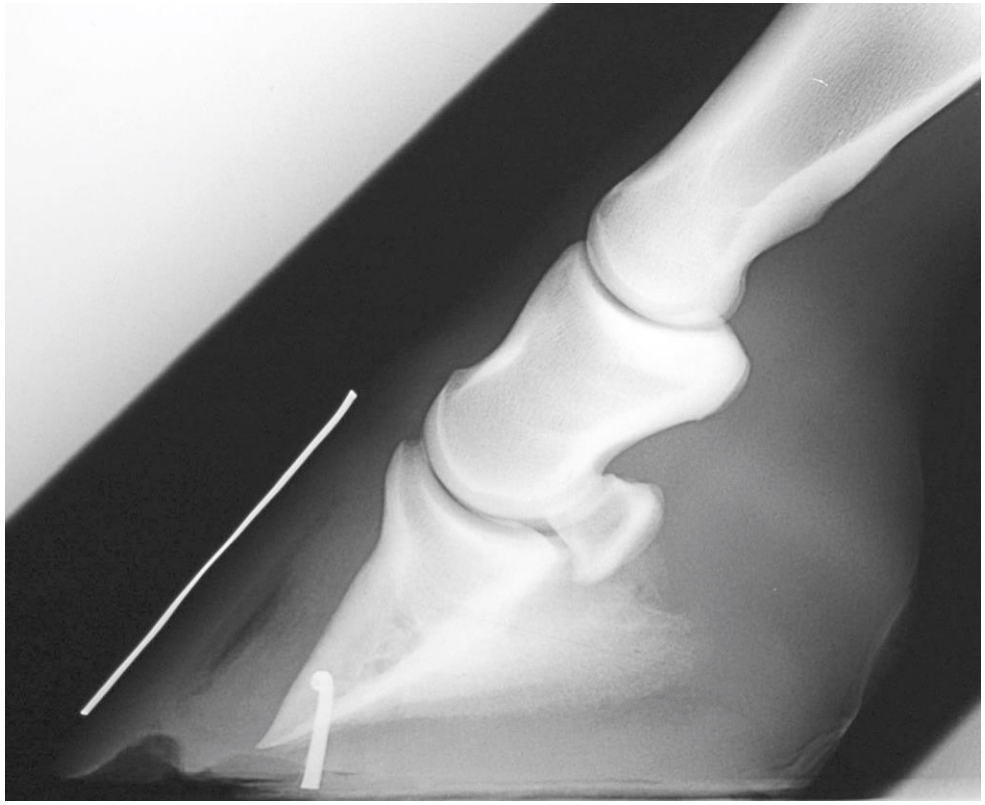

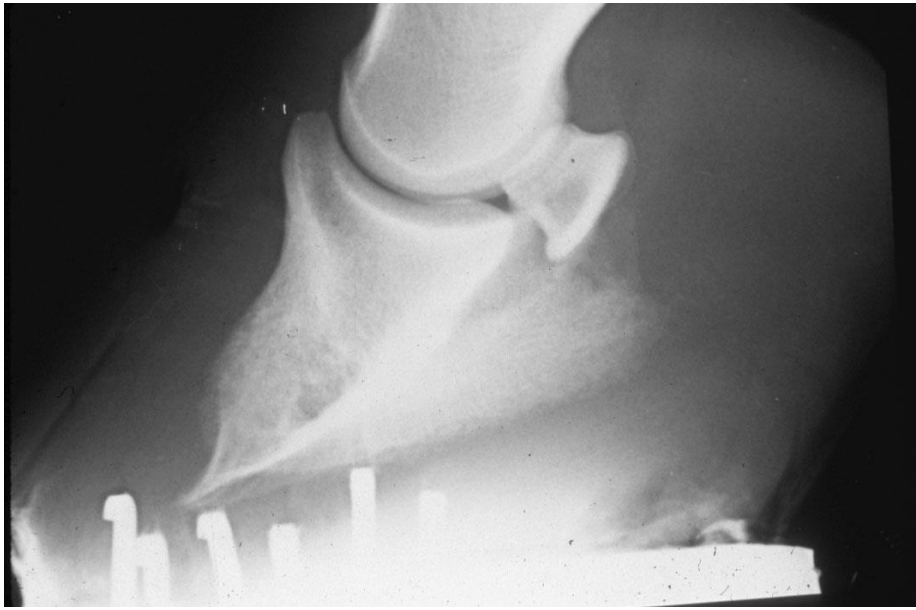

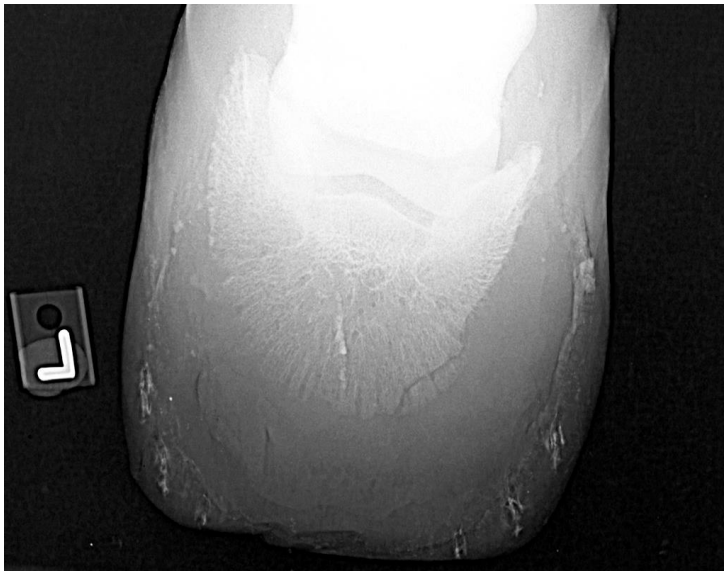

Treatment/Prevention

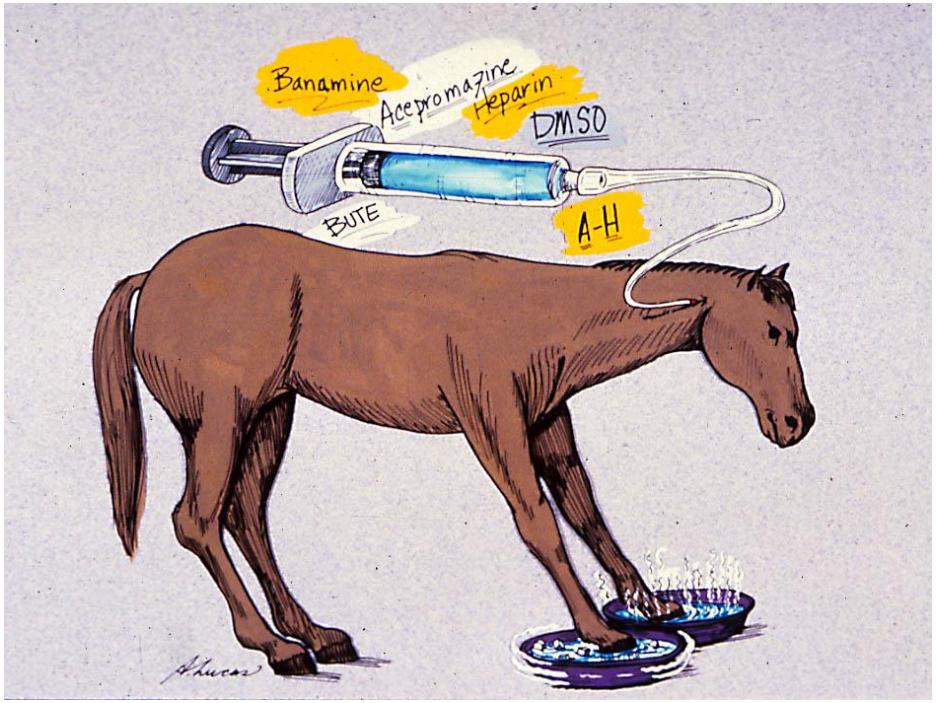

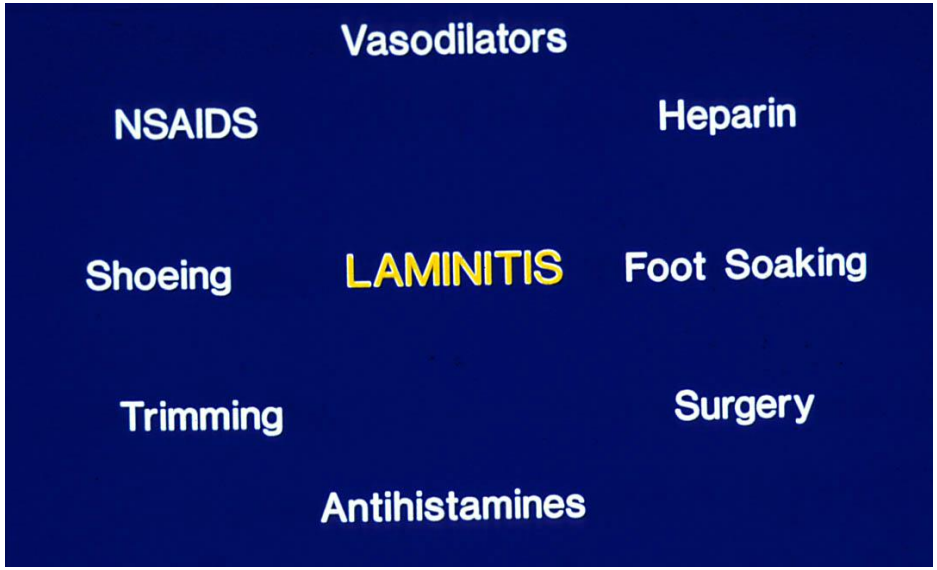

Developmental – to prevent disease progression
Acute – to minimize severity of laminar damage
Chronic – to limit further movement of coffin bone

Treatment

- Remove or treat inciting cause
  - Minimize toxemia or “trigger factors”
  - Mineral oil, flunixin meglumine, DMSO
- Cushing’s – pergolide
- Metabolic syndrome/IR
  - Decrease glycemic index (CHOs)
  - Pergolide and thyroxine?
- Mechanical
  - Sling/ improve weight bearing on other limb
  - Support of contralateral foot

Treatment

- Dependent on stage of disease
  - Cryotherapy (ice) in acute stage?
  - Vasodilatory drugs?
  - Anti-inflammatory drugs
  - Pain control (decrease sympathetic response)
- Minimize toe length (remove shoe)
  - Bevel dorsal hoof wall of toe
- Increase weight bearing surface area
  - Styrofoam, sand, frog pads, soft putty
  - Corrective shoeing

Initial Foot Support

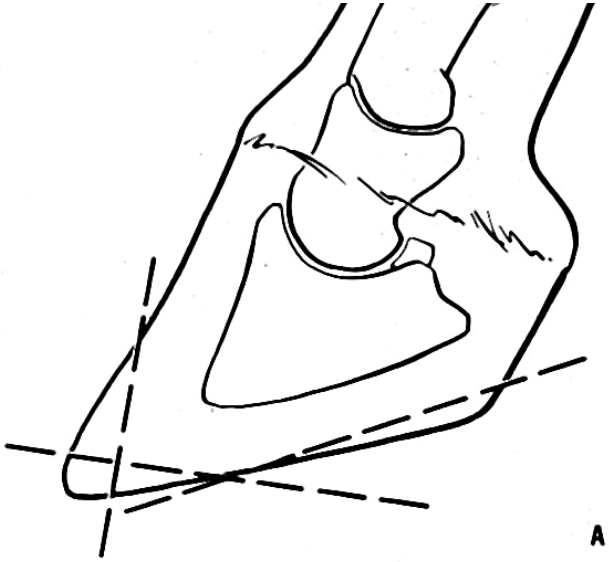

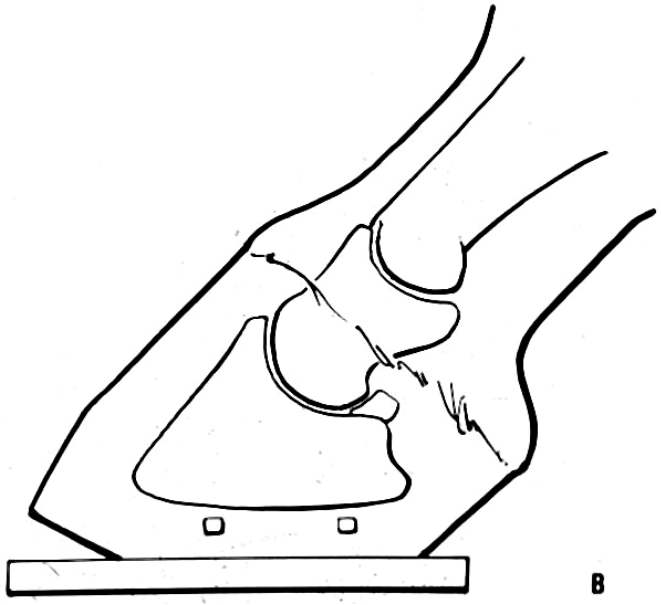

Corrective Shoeing

Foot Preparation

6-year old App. Stallion

- Unilateral right forelimb laminitis
- No known predisposing cause (toe grabs and long toe?)

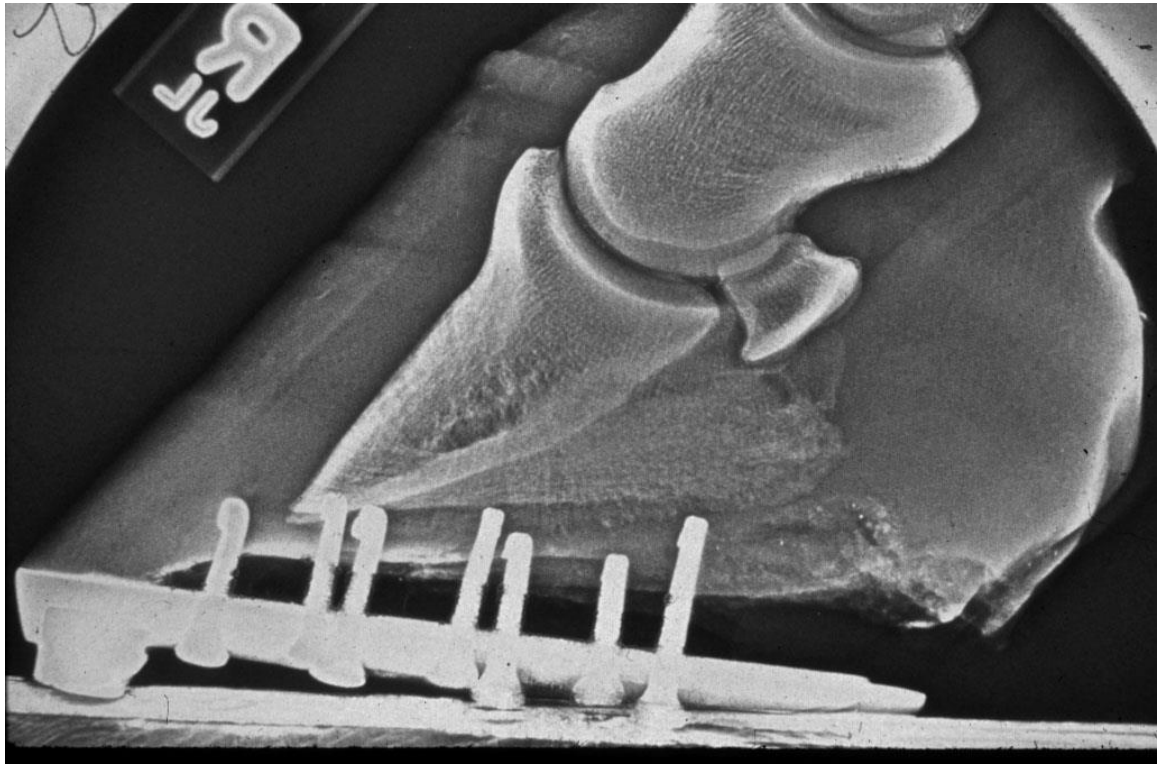

Removed shoe, shortened toe, and applied a lily pad for frog support

Follow-up Radiographs

10 days

4 weeks

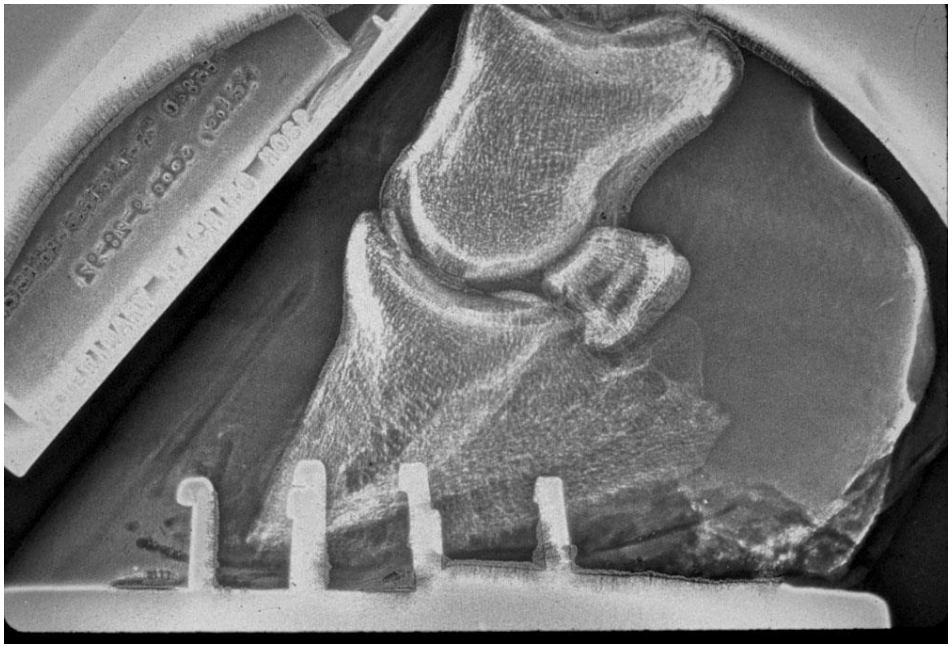

Progressive rotation of coffin bone
Abscess developed at toe region
Performed unilateral deep digital flexor tenotomy
Applied extended heel shoe with a treatment plate

Thank you from CSU-VTH